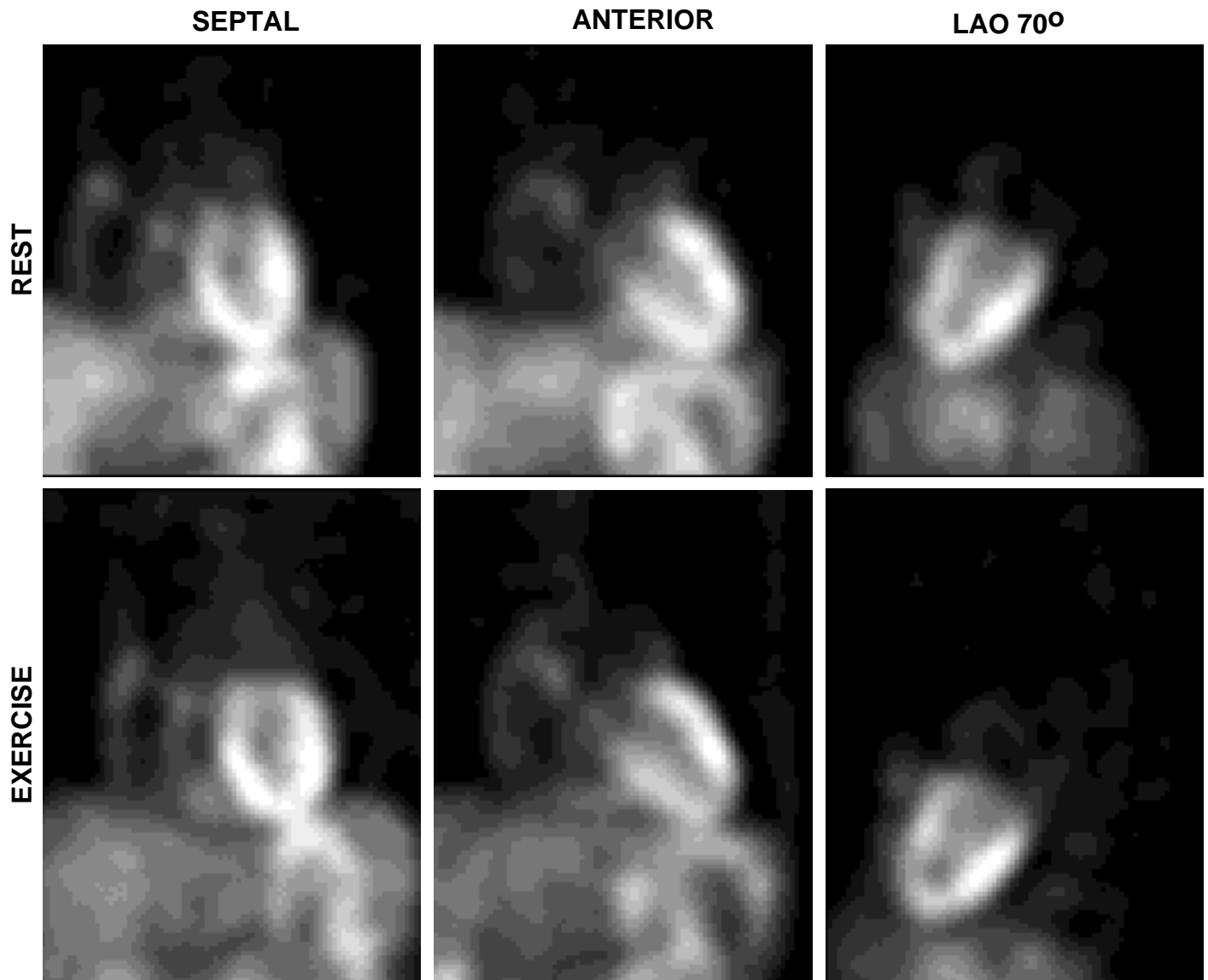


CARDIAC SPECT (Thallium 201): CASE STUDY



Diagnosis: Prominent (normal) atrial activity

Full history: This patient is an 83 year-old woman with a history of atrial fibrillation, congestive heart failure, and hypertension, who is being evaluated to rule out ischemia prior to receiving ECT treatment for refractory depression.

Findings: Myocardial Imaging (Dipyridamole/Redistribution-planar only):

1. Normal variant with prominent activity seen in all four chambers.
2. No evidence of ischemia.

Followup: Comparison with a chest radiograph confirmed the unusual uptake to be in the expect region of the atria, which can be seen as a normal variant. The patient has no history of malignancy, making uptake by mediastinal tumor unlikely.