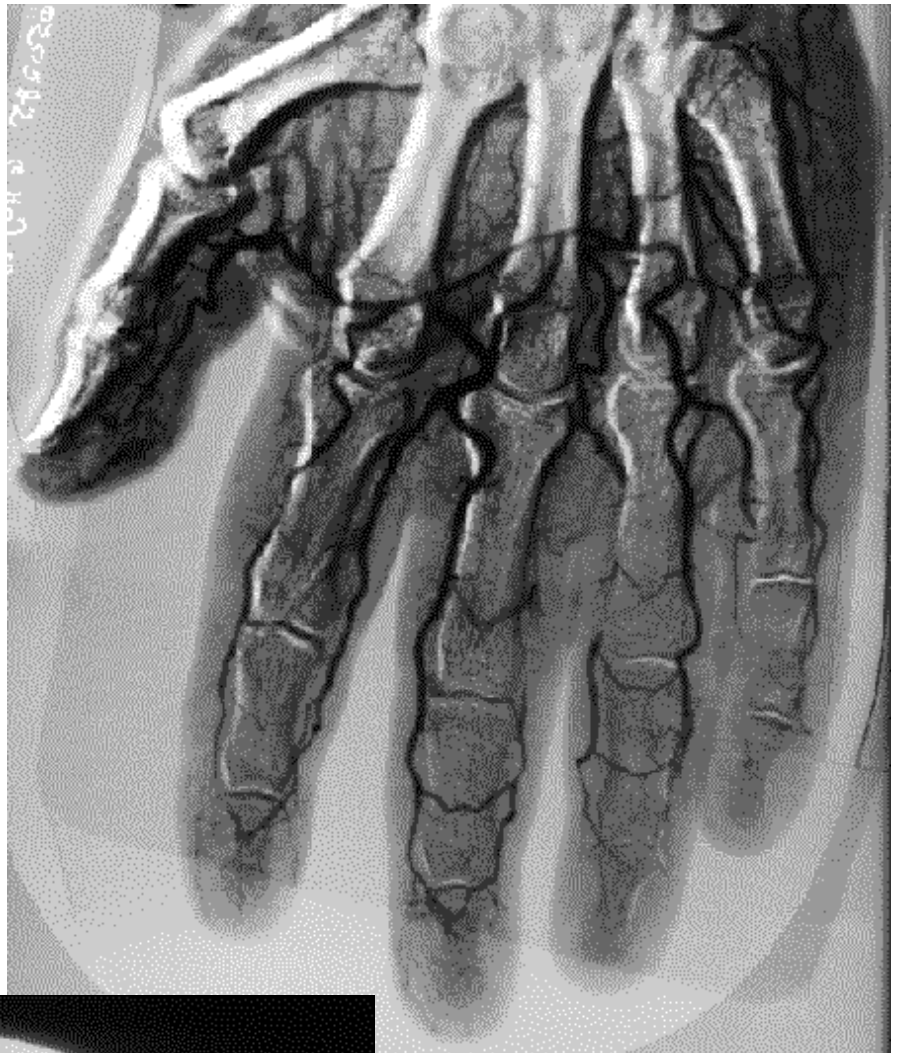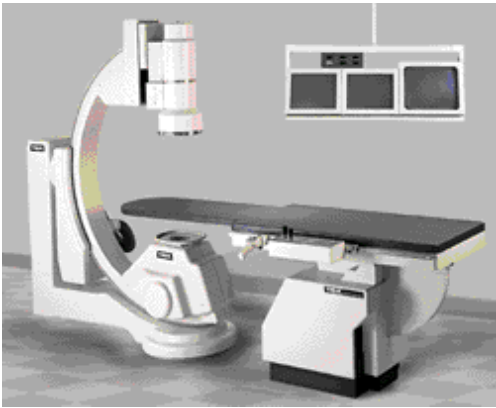

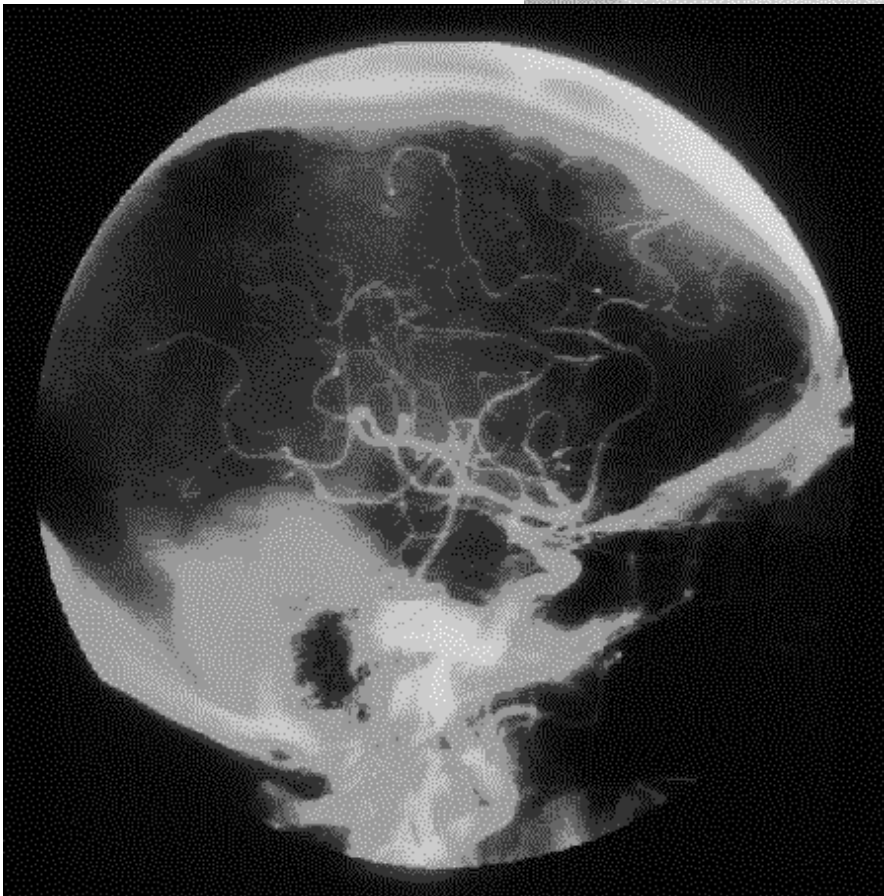
X-RAY ANGIOGRAPHY



Hand



Cerebral Vessels